

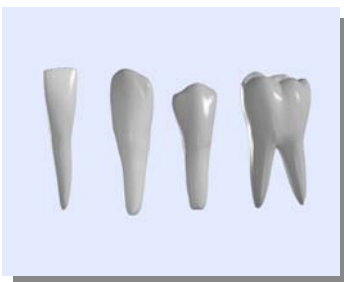*DVD about oral care for people  
with special needs*

**Instructions for healthcare personnel**



**ORAL HEALTH AND PREVENTION**

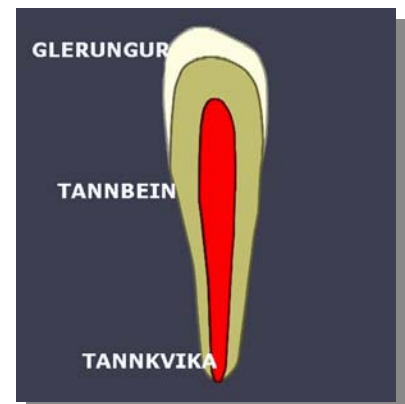
Clean and healthy teeth are important for our wellbeing. Oral health is primarily a matter of good oral hygiene, healthy eating and drinking habits, use of fluoride, and regular dental check-ups. In modern society it is entirely possible for people to keep their own teeth throughout their lives.



Teeth vary in size and shape: incisors, canines, premolars and molars.

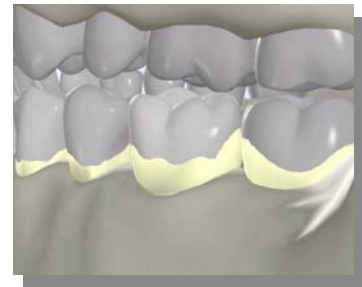
A tooth comprises two parts: crown and root. The crown is the visible part of the tooth, which projects into the oral cavity, while the root is the hidden part, which is rooted in the jawbone.

The crown is surfaced in enamel, beneath which is dentine. The reddish area in the middle is known as pulp. Around the root is connective tissue which attaches the tooth to the jawbone. The gums are pale pink in colour, and are tightly moulded to the teeth.

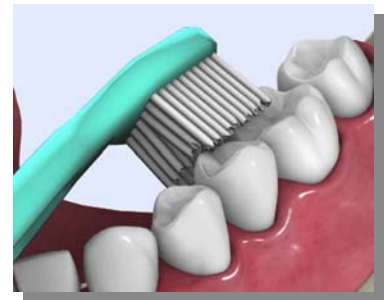

## ORAL HYGIENE

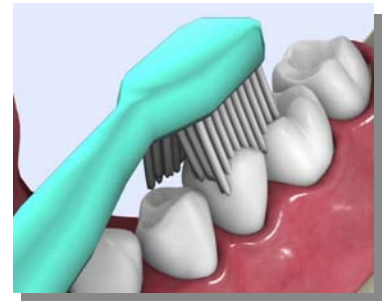
Hygiene is necessary to every person, and clean teeth are no exception. The mouth contains bacteria which can damage teeth and gums. Certain bacteria attach themselves to the teeth to form plaque, a whitish film which adheres to the surface of the enamel. The more frequently sugary foods are eaten, the faster the plaque will form. Plaque must be removed regularly, in order to prevent oral ailments such as dental decay and gingivitis (inflammation of the gums). Plaque which is left on the teeth for a long time absorbs minerals and forms dental calculus (tartar). Tartar contains germs which can cause irritation in the gums.



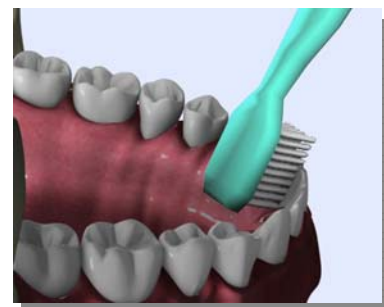It is important to allow plenty of time (2-3 minutes) for brushing. Start, for instance, on the insides of the teeth, on the left. The brush hairs should be placed obliquely to the gums. Press on the brush, with the hairs between the teeth and the gum line, and rub away from the gums. Brush back and forth with short strokes.



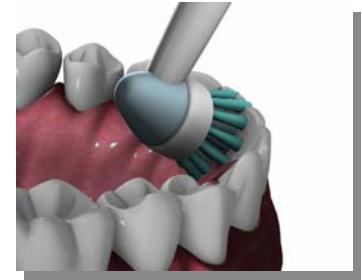
Then brush the biting surface of the molars, making sure to brush the fissures thoroughly to remove plaque. Continue to the outer surface of the molars, and remember to brush thoroughly behind the back tooth. Brush the canine and incisor areas thoroughly. When the back of the incisors is brushed, the brush must be held vertically and moved up and down. Then continue with the other three sectors of the mouth.



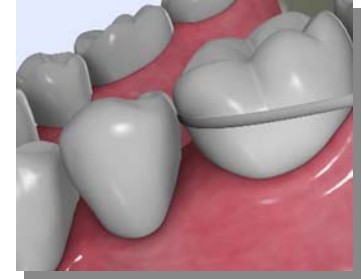
Use of a soft, dense brush and fluoride toothpaste is recommended. Do not rinse the mouth after brushing. The fluoride in the toothpaste will remain active for longer if the mouth is not rinsed. Swallowing a little toothpaste does no harm.



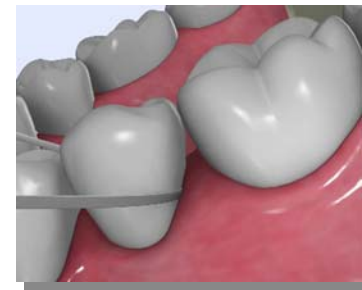
Electric toothbrushes are useful for dental care, but must be used correctly. The brush is placed against the tooth surface, and kept in the same place for about three seconds, following the curve of the tooth surface. Then the brush is moved to the next tooth, and each tooth surface brushed: outside, inside and chewing surfaces.



Floss should be used to clean between the teeth at least once a day. Cut a length of floss long enough to wind around the fingers, then carefully insert it between the teeth and down to the gap between teeth and gum. Pass the taut floss up and down on each side. The floss must be held firmly against the tooth surface throughout. Floss all the gaps between the teeth in the upper and lower jaw. If the gums bleed, this is a sign of inflammation of the gums, indicating that even better oral hygiene is required.



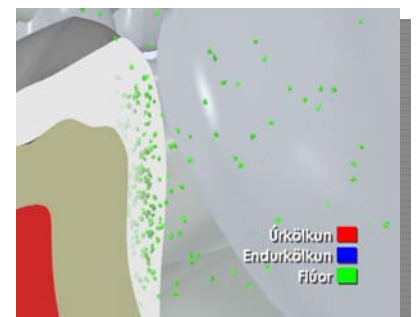
Interdental brushes can be used to clean larger gaps between teeth and gums. They are also useful for cleaning around bridges and implants. Insert the interdental brush carefully, and brush back and forth against the tooth surface 5-8 times.



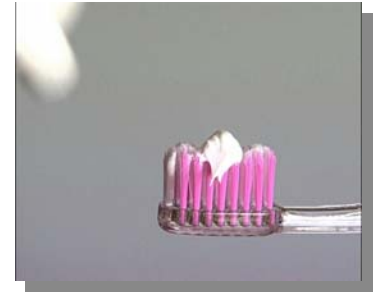
## FLUORIDE

Use of fluoride is recommended to prevent dental decay. Fluoride is the most important ingredient of toothpaste, and it affects the chemical processes which are constantly taking place in the dental surface. If there is sufficient fluoride in the mouth, it can contribute to remineralisation, and can reverse early-stage dental decay.

Toothpaste should be applied to cover about one-third of the head of the toothbrush. The frequency and duration of fluoride being in contact with the teeth is important, so leave the toothpaste in the mouth. Do not rinse after brushing. Simply spit out the excess.

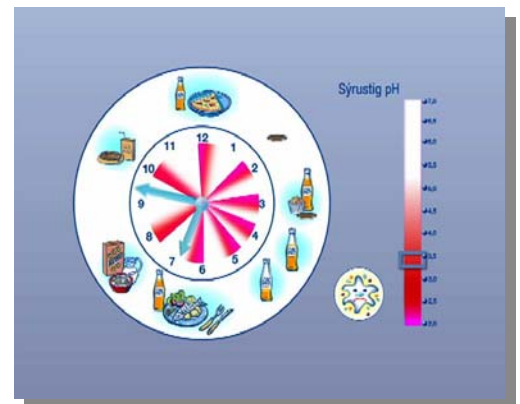


Fluoride chewing gum can be useful for people whose saliva production is limited, and also for anyone whose risk of dental decay is increased for any reason. Some diseases and medications, as well as dry mouth and poor diet, lead to increased risk of dental decay, and in such cases it is advisable to increase fluoride use, for instance by rinsing the mouth regularly with a fluoride mouthwash.

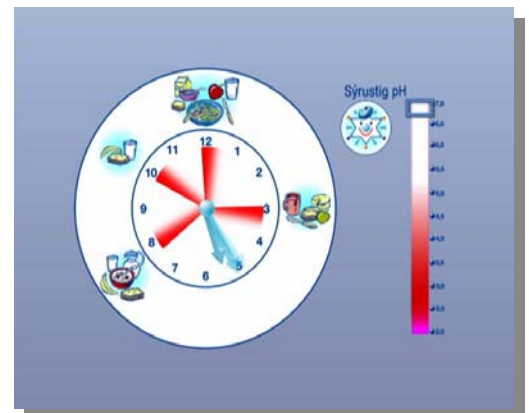


## EATING AND DRINKING HABITS

Healthy eating and drinking habits are the basis of good oral health. Bacteria which adhere to the surface of teeth transform sugars from food into acids, which release minerals from the teeth for about half an hour after sugary food is eaten. A person who is always nibbling at sweet foods and drinking acid drinks will always be in the “red” or “pink” sector of the scale, with an increased risk of dental decay and erosion of enamel.



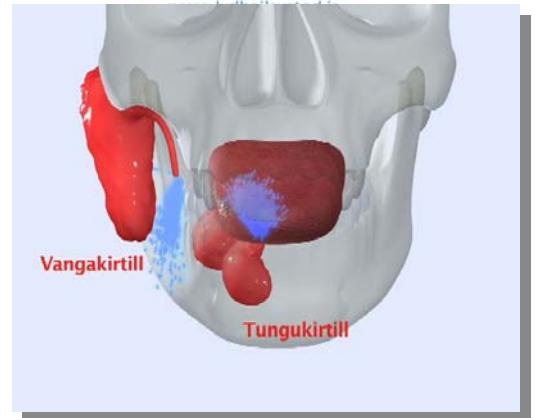
Saliva plays a key role in the body’s defences against dental disease. If the interval between meals is normal, the body’s defences can successfully resist acids and dental decay, and enamel erosion is controlled. A piece of cheese after a meal protects the teeth, and the same is true of sugar-free gum. Constant snacking is too much for the defensive system to cope with.



## SALIVA

Adequate saliva production is vital to wellbeing, and maintains oral health through a neutral pH level (neither acid nor alkaline). The saliva flows from salivary glands which are located in the floor of the mouth and in the cheeks. Dry mouth can be a side-effect of certain diseases and medications; the symptoms are soreness of the mouth, and difficulty in speaking, chewing and swallowing. Persistent dryness of the mouth leads more, and faster, tooth decay.

The incidence of problems with oral mucous membranes and gums also increases. Problems also often arise with use of dentures. Good oral hygiene is always important, and even more so where the mouth is dry.



## DENTAL EXAMINATION

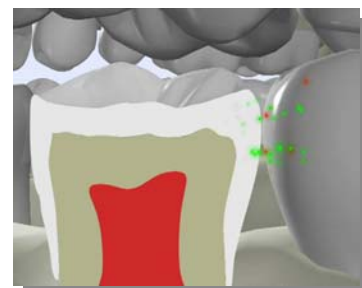
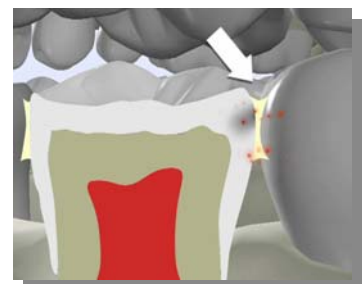
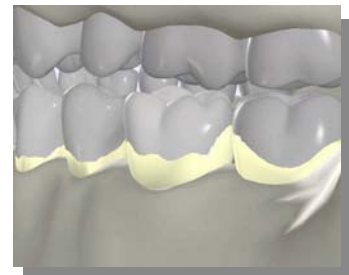
Regular dental check-ups are a vital aspect of dental care and treatment. The frequency of check-ups varies from person to person, in accord with their risk level, but visiting the dentist at least once a year is recommended.

## DENTAL DISEASES

### DENTAL DECAY/CARIES

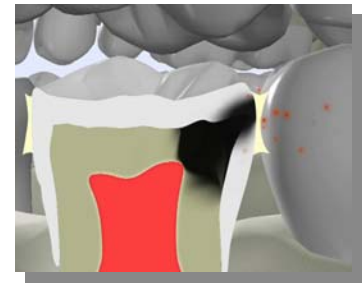
Certain types of bacteria adhere to the surface of the teeth and form a film (plaque), which must be removed by regular brushing at least twice daily. If a person is constantly snacking, so that the sugar level in the mouth is high, plaque forms more rapidly. If oral hygiene is poor and plaque builds up, it prevents saliva reaching the surface of the teeth, leading to tooth decay. Bacteria in the plaque convert sugars from food into acids, which dissolve the surface of tooth enamel, and minerals leach out.

The dark spot visible here is dental decay at an early stage. Acids have dissolved the dental surface. While the decay is confined to the enamel, it can be stopped or reversed by improved oral hygiene, additional fluoride treatment and better eating and drinking habits. Enamel dissolves rather slowly, but when the decay has eaten through the enamel to the dentine the decay progresses more rapidly. At this



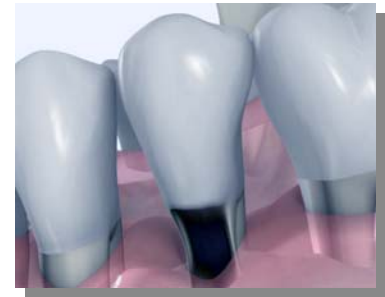stage a dentist must remove the decayed tissue and fill the tooth.

When tooth decay approaches the pulp and the tooth becomes infected, inflammation results, which leads to pressure and toothache.



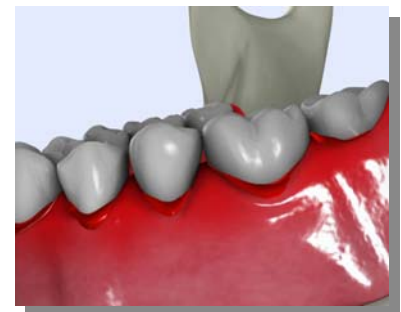
## ROOT DAMAGE

Root damage is a growing problem among the elderly. The gums may shrink, leaving part of the root exposed, and unprotected by the mucous membrane; this becomes an ideal site for plaque. The unprotected root is highly susceptible to decay, and additional fluoride treatment is absolutely necessary in order to hinder decay of the dental root.



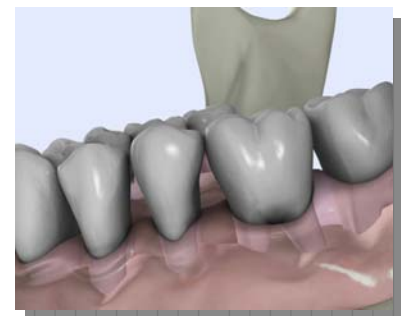
## GINGIVITIS

The teeth are rooted in the jawbone, where they are fixed by narrow threads of connective tissue. Healthy gums tightly surround the tooth like a snug collar, and are pale pink in colour. Gingivitis (inflammation of the gums) is caused by the body's immune reaction to the bacteria in plaque on the dental surface. The bacteria are thus an irritant, without entering the connective tissue itself. The gums become red and swollen, and bleed easily. The inflammation disappears if oral hygiene is improved.



Persistent gingivitis often leads to more serious periodontal (gum) diseases. The inflamed gum tissue can become separated from the tooth, and the inflammation spreads to the periodontal fibres.

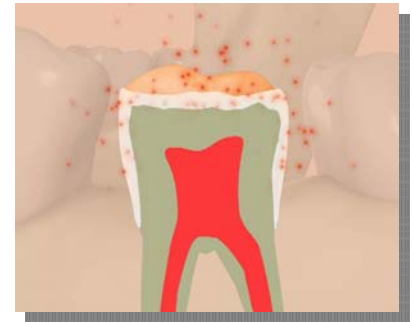This leads to damage to the periodontal fibres and the jawbone, and the teeth gradually loosen. Smoking triples the risk of periodontal inflammation, although the symptoms are generally less severe. Gingivitis often causes little or no discomfort, and thus diagnosis is often delayed. It is vital to prevent the problem through good oral hygiene, before it takes hold.



## ENAMEL EROSION

When the environment of the mouth is in equilibrium, the flow of minerals out of the surface of the teeth and into it is equal. Saliva maintains the correct pH balance, but if a person drinks an acid drink the acidity rises, and minerals leach out of the teeth. Enamel erosion takes place when acids eat away the surface of the tooth, eroding the enamel. Acids remove minerals from the enamel, and they cannot be reabsorbed if the environment of the mouth remains acid. If an acid drink is drunk every 10 to 15 minutes, for instance, the saliva can never reduce the pH level of the mouth to a neutral level.

The enamel grows thinner, and the teeth become more sensitive to heat and cold. It is advisable to limit consumption of acidic drinks to certain times of the day, or of the week, in order to prevent enamel erosion. Water is the best drink!



## ORAL HYGIENE FOR THOSE WHO HAVE THEIR OWN TEETH

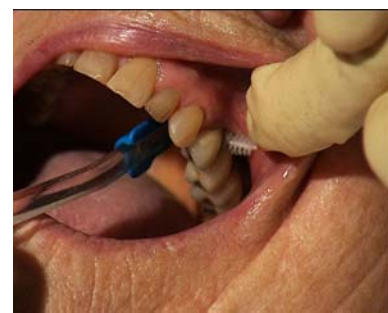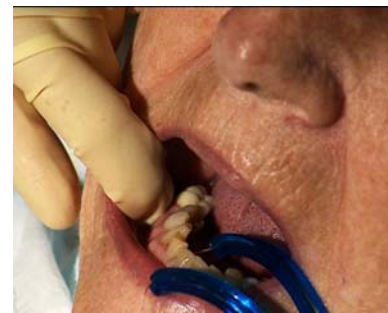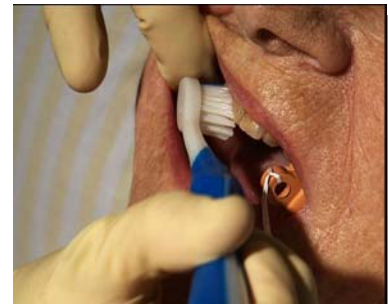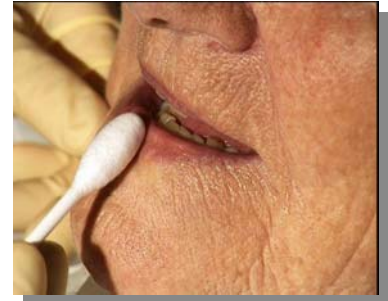### ORAL HYGIENE FOR PATIENTS

Long-term illness increases the likelihood of oral health problems. People with disabilities, ill and elderly people require help from healthcare personnel with their oral hygiene. Good oral hygiene is essential if natural teeth, implants and bridges are to continue to serve their purpose in the long term. In healthcare facilities, nursing homes and in home nursing, oral hygiene must be part of the routine of daily care. It is important to provide appropriate assistance as required by each individual.

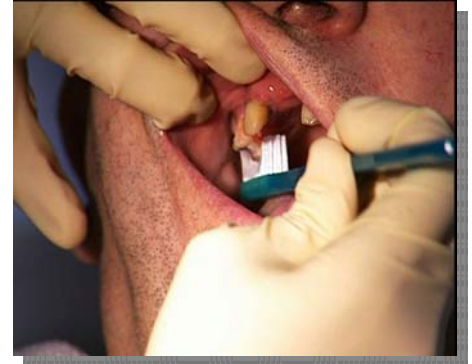In oral care of very ill patients it is important to explain what is happening, raise the head, and spread a towel over neck and chest. Hands must be washed, and gloves used.

Start by applying Vaseline to the lips, and open the mouth by gently grasping the patient's chin. A swab can be used to open the mouth. It is advisable to use a bite block between the molars to keep the mouth open, and it is a good idea to fix dental floss to the block. The upper and lower teeth on the right are then brushed with a low-foam toothpaste with high fluoride content, and occasionally with chlorhexidine. When the bite block is transferred to the other side of the mouth the swab can be used to open the mouth a little more. Clean the surfaces between the teeth with floss.

If the patient has bridges, implants or overdentures use interdental brushes with chlorhexidine. Use only a small quantity of chlorhexidine, as there is a risk of it entering the respiratory tract of very ill individuals. Floss with a stiffened end can also be used, and passed along the teeth and gums. Finally wipe the mucous membranes with damp gauze or an oral swab, and apply Vaseline to the lips. A bite block can be improvised from 4-5 tongue depressors, taped together and wrapped in gauze.



Many people have a removable partial denture. This is removed before brushing the natural teeth. The teeth are brushed on all sides using a soft brush and fluoride toothpaste, and occasionally with chlorhexidine. Do not be put off by a little bleeding from the gums, simply brush better. Encourage the patient to rinse the mouth with lukewarm water. Finally, apply a little fluoride toothpaste to the surface of the teeth. The denture is also thoroughly cleaned.

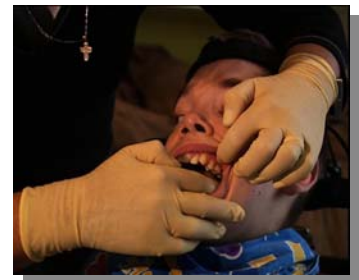

If the patient is on medication, ensure that it is swallowed at once. Tablets which are held in the mouth for a long time can damage the mucous membrane. No medications containing sugar or syrup should be used, only sugar-free versions should be used.

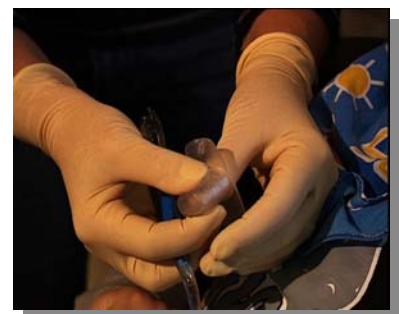
Those who are not fed by mouth still form plaque on their teeth and tongue, which must be removed by good oral hygiene at least once a day. It is also advisable to moisten the gums, tongue, mucous membrane and lips every 4-5 hours with water or artificial saliva.

## **ORAL HYGIENE FOR PEOPLE WITH DISABILITIES**

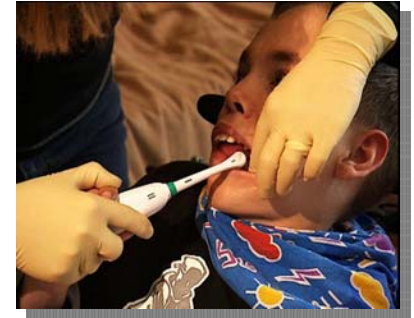Oral hygiene must be a part of the daily routine of people with disabilities. It is important to provide the appropriate assistance required by each individual. While most disabled children's teeth are initially as healthy as those of other children, they are far more likely to have oral problems. Some bite or gag when their teeth are brushed, or refuse to allow anyone to touch their mouth. Medication can lead to severe dryness of mouth, and certain medications cause gingivitis. Disabled people with limited motor control require full assistance in oral hygiene.



Give yourself plenty of time. Explain what is happening, and follow the individual instructions, for instance on the oral care information form. Find out how far the person can tolerate being touched in the mouth area, and gradually increase this tolerance. Always use gloves. It is advisable to use a finger guard or bite block to keep the mouth open.



The lips and cheeks must be lifted to give a clear view. The teeth are brushed with a manual or electric toothbrush and fluoride toothpaste. The spaces between teeth are flossed. Chlorhexidine should be used occasionally. Electric toothbrushes are highly suitable for brushing the teeth of handicapped people. It is a good idea to wipe the tongue and mucous membranes with damp gauze after brushing, and apply cream to the lips and cheeks.



It is important to find the best posture for cleaning another person's teeth. For a person in a wheelchair, it can be convenient to stand behind the chair. Brushing while the person is lying down may also be a good solution. The person should be familiarised with his/her own oral hygiene equipment, and oral care should take place in a familiar surroundings where stress is minimised.

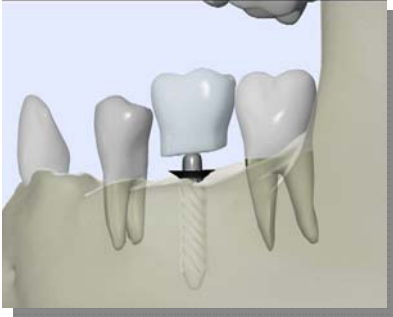All individuals are encouraged to participate in their own oral hygiene as far as possible, but many disabled people require full assistance with cleaning their teeth at least once a day. Some disabled people are largely able to manage their own oral hygiene, but they require supervision. Oral care equipment must be renewed regularly.



Healthcare personnel is responsible for providing expert assistance where teeth or dental prosthetics are hard to clean.

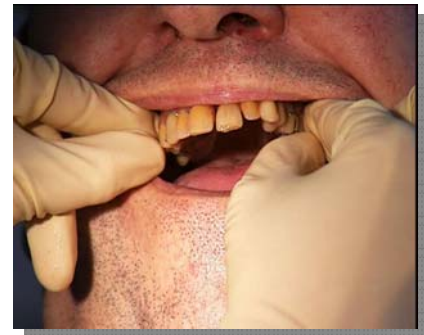## ORAL HYGIENE FOR THOSE WITH REMOVABLE DENTURES

### PARTIAL DENTURES

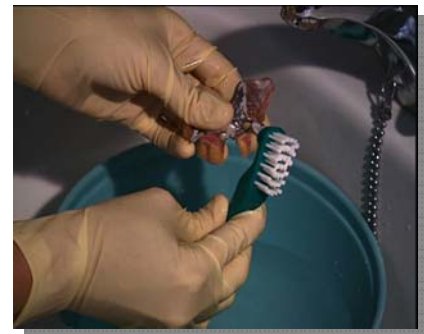


Keeping one's natural teeth is ideal, but if one or more teeth are missing there are various options: implants, fixed bridges, or removable partial or complete dentures can be fitted. In some cases implants can be embedded in the jawbone, so that dentures can be fixed more securely.

If only a few natural teeth remain in the mouth, they must be kept clean, and mucous membranes must be kept in good condition, so that the denture continues to be usable. The denture is removed from the mouth, taking care not to bend the metal parts. Carefully insert a fingernail under the retainer on each side and press slightly to detach the denture. The teeth are brushed on all sides with fluoride toothpaste, and occasionally with chlorhexidine. Clean the oral cavity thoroughly with a damp sponge or gauze. Do not forget to clean the tongue.



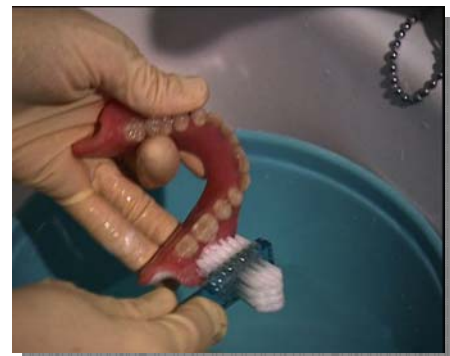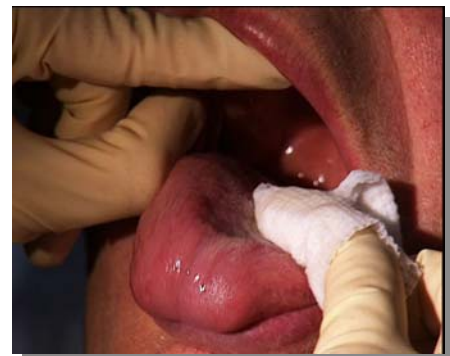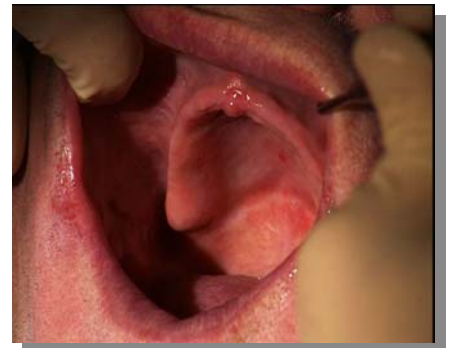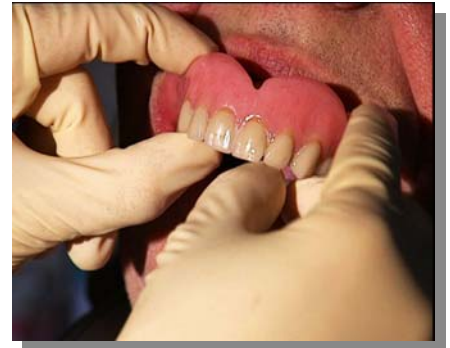When cleaning the denture, it is advisable to have a bowl of water in the sink beneath it, to avoid breakage if the denture is dropped. Use a special toothbrush for cleaning the denture, and clean it thoroughly all over, inside and out. Brush the nooks and crannies well with the narrow end of the brush. Use a mild liquid soap, or a specialised cleaning agent for the purpose, available at pharmacies. Never use toothpaste, as it contains abrasives which could scratch the plastic parts of the denture. Finally rinse the denture thoroughly in cold water and leave overnight in cold water, or return to the mouth.



## COMPLETE DENTURES

If there are no natural teeth in the mouth, the dentures must be kept clean, and the mucous membrane beneath must be kept healthy. Here an upper denture is removed from the mouth. If the denture is very firmly fixed, insert the index finger gently between the denture and the cheek, and press the denture downwards. Remove the lower denture in the same way. When the dentures have been removed, it is a good idea to examine the oral cavity thoroughly. Look for reddening or sores which may form when the gums shrink and the dentures no longer fit properly. This individual has sores in the corners of the mouth, which may be due to ill fitting dentures, bacterial infection, a fungal infection or vitamin shortage. In such a case a dentist or doctor should be consulted. The oral cavity is cleaned thoroughly with a moist sponge or gauze, and the lips are wiped. Do not forget the tongue, which should be wiped 2-3 times.

When cleaning dentures, it is advisable to have a bowl of water in the sink beneath it, to avoid breakage if the denture is dropped. The photo shows how to hold a denture for cleaning. Clean it thoroughly all over, inside and out, with a special toothbrush and a mild liquid soap, or a specialised cleaning agent for the purpose, available at pharmacies. Never use tooth-paste, as it contains abrasives which could scratch the plastic parts of the denture. Finally rinse the dentures thoroughly in cold water and return to the mouth, or leave overnight in water. Complete dentures must always be kept in water. If they dry out, they may become warped. When the dentures are replaced in the mouth, make sure that the lips are not caught and pinched.



### Useful tips:

- It is recommended that dentures be sterilised at least once a month by soaking overnight in a 0.2% solution of chlorhexidine.
- Tartar (calculus) can be removed by soaking the denture overnight in a vinegar solution (1 cup of water/1 teaspoon of vinegar) when necessary.
- Staining by coffee/tea can be reduced by soaking the denture in a solution of baking soda (sodium bicarbonate) - one cup water/1 teaspoon baking soda - for about ten minutes when required.

*Hólmfríður Guðmundsdóttir, DDS, Ms*

*The Primary Health Care/Centre for Oral Health & The Public Health Institute of Iceland*